

The Role of Imaging in the Diagnosis of Diabetic-Related Foot Osteomyelitis



Anthea Hon1

1 Westmead Hospital, Sydney, Australia

BACKGROUND

Osteomyelitis is a complicated problem characterised by progressive inflammatory destruction of bone. Osteomyelitis associated with diabetes is the most common presentation worldwide and the foot is the most frequently affected site, occurring in 15% of diabetics. Furthermore, diabetic persons have an approximate 25% lifetime risk of developing foot ulcerations with clinically infected foot ulcers having a prevalence of osteomyelitis as high as 66%.¹ The presence of osteomyelitis in diabetic-related foot infections significantly increases the individual's chance of amputation, in which diabetic foot infections account for 60% of non-traumatic lower limb amputations and recurrent infections commonly occur in up to 36% of patients.² The cost to the health care system for treatment and hospital stays as a result of diabetes is \$990 million annually.³ Imaging of the infected diabetic foot with suspected osteomyelitis plays an important role in the early detection of the suspected clinical diagnosis of the infection process, so as to accurately guide treatment and potentially help reduce incidences of extended duration of hospitalisation and major limb amputation.

AIM

The purpose of this study was to evaluate the role of plain radiography and MRI in the diagnosis of diabetic-related osteomyelitis of the foot, in order to determine which technique is superior in the early diagnosis of osteomyelitis in the infected diabetic foot.

METHOD

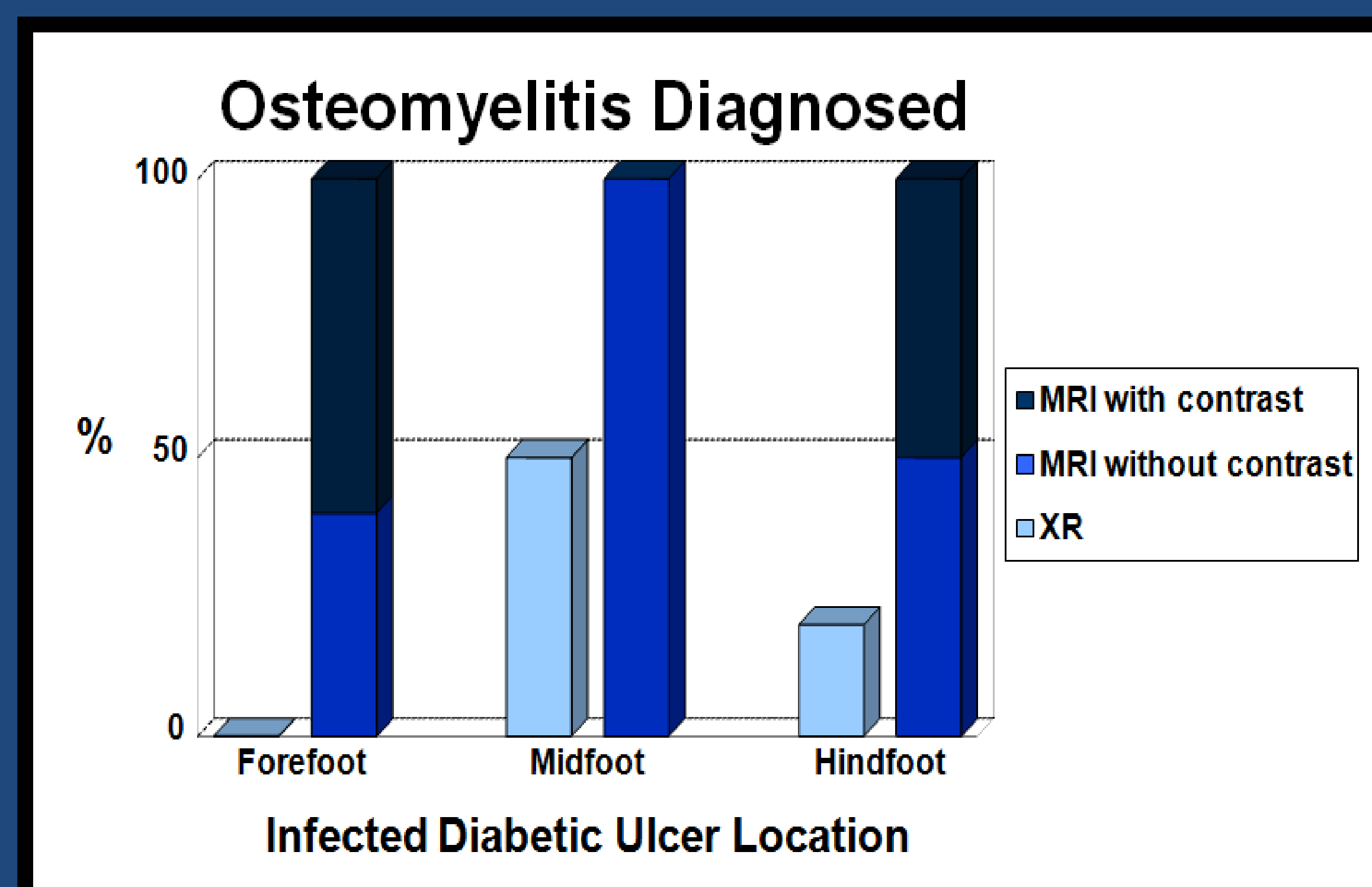
The imaging of 14 diabetic patients (2 females, 12 males, mean age 66.2 years, range 39-86 years old) with unilateral infected ulcer affecting the forefoot in ten cases, the midfoot in two and the hindfoot in two, clinically suspected of having osteomyelitis were retrospectively evaluated. Plain radiographs, MR images and reports of the affected foot were retrospectively reviewed. Anterior-Posterior, Oblique and Lateral plain radiographic projections were performed on a Philips Diagnost Digital System (Philips Healthcare, Best, Netherlands). Sagittal and Long axis T1-W, Sagittal T2 fat suppressed or STIR-W, Long and Short axis proton-density fat-suppressed-W, Sagittal and Short axis T1 fat suppressed-W post contrast MRI sequences were also performed of the affected foot within 7 days of the plain radiography examinations on a 3-Tesla superconducting magnet (Signa Excite Twinspeed, GE Healthcare, Milwaukee) using a dedicated foot coil.

RESULTS

MRI consistently confirmed the diagnosis of osteomyelitis in 100% of patients. Plain radiography however, was non-specific and insensitive in its diagnosis, demonstrating osteomyelitis definitively in only 21% of patients (Figure 1 and Graph 1).

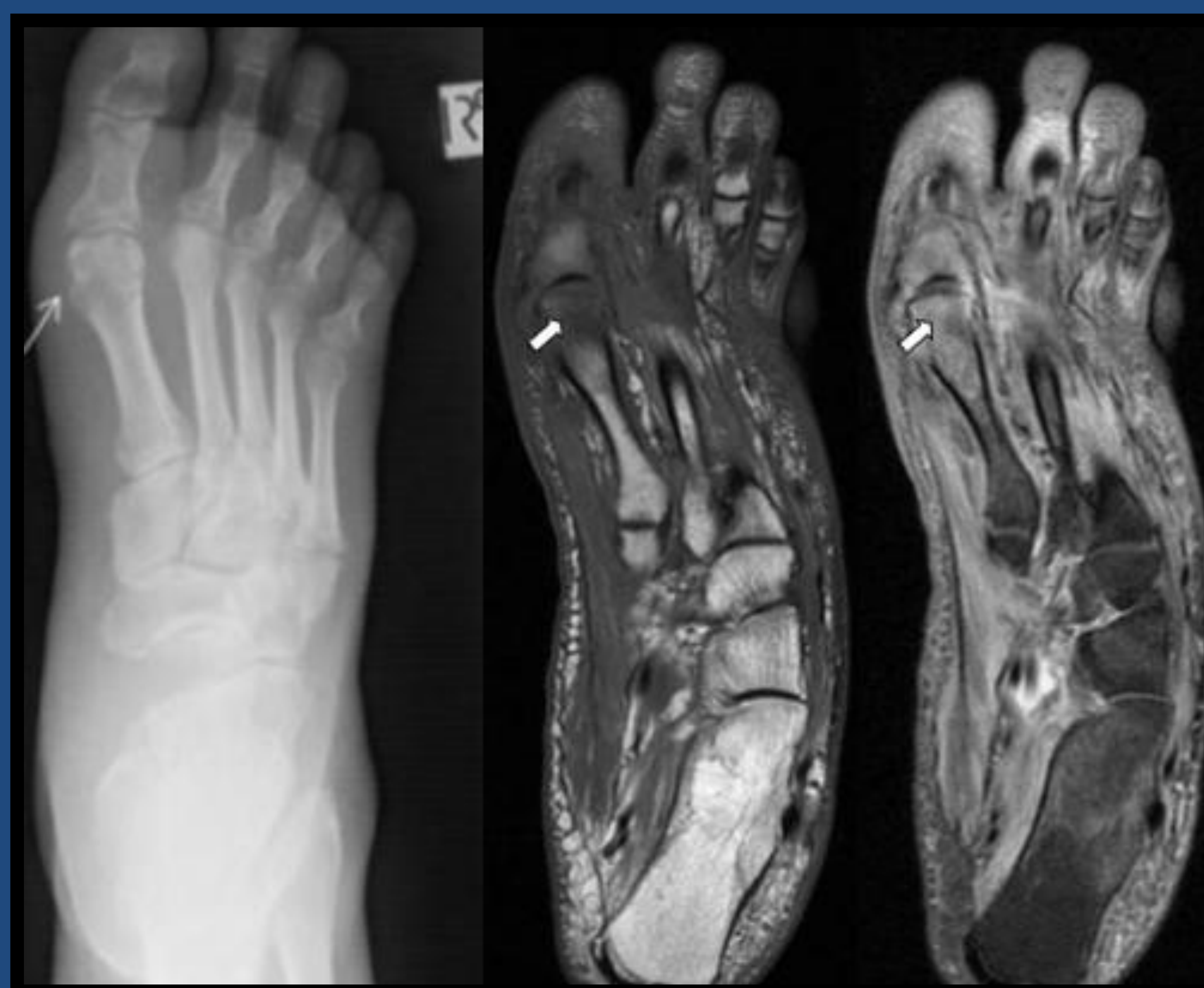

Figure 1 - (Left) AP view shows destructive process and osteolysis (white arrow). (Middle) Long axis T1-W; (Right) Long axis PDFS-W shows osteomyelitis characterised by low T1 and high PDFS signal intensity of marrow (white arrow).



Graph 1 - Confirmed diagnosis of osteomyelitis using plain radiography and MRI with and without contrast.

ACKNOWLEDGEMENTS

Many thanks to Sheryl Foster and Megan Cromer for their help and support throughout this work.

DISCUSSION

MRI has the ability to provide anatomical details in addition to detecting abnormalities within the bone marrow, joint spaces and surrounding soft tissue when radiographic findings are inconclusive and even absent. Further, it was found that the administration of a contrast agent may not be necessary for the early diagnosis of osteomyelitis in patients with infected diabetic foot ulcers; the use of T1-W and STIR-W sequences alone may be sufficient for its early detection or exclusion. Due to the non-specific nature of radiography, there is an argument for proceeding straight to an abridged MRI examination in this patient population in order to make an early diagnosis and implement appropriate therapy. This approach also has the potential for significant savings in health costs.

CONCLUSION

The findings of this retrospective study have shown that MRI is a superior modality to that of plain radiography in the early diagnosis of osteomyelitis in the infected diabetic foot. The use of MRI in the diagnosis of this condition has the potential for better patient outcomes along with the potential for healthcare cost savings.

REFERENCES

- 1 Thomas-Ramoutar C, Tierney E, Frykberg R. 2010. Osteomyelitis and Lower Extremity Amputations in the Diabetic Population. *The Journal of Diabetic Foot Complications*, 2.
- 2 Ertugrul MB, Baktiroglu S, Salman S, Unal S, Aksoy M. 2006. The diagnosis of osteomyelitis of the foot in diabetes: microbiological examination vs. magnetic resonance imaging and labelled leucocyte scanning. *Diabetic Medicine*. 23:649-653.
- 3 Australian Institute of Health and Welfare 2012. Diabetes: the facts. <http://www.aihw.gov.au/diabetes/>.